

Cutaneous Manifestations in Chronic Hemodialysis Patients in Antananarivo Madagascar

Mendrika Fifaliana Rakotoarisaona, Fandresena Arilala Sendrasoa, Malalaniaina Andrianarison, Onivola Raharolahy, Naina Harinjara Razanakoto, Moril Sata, Volatantely Ratovonjanahary, Irina Mamisoa Ranaivo, Lala Soavina Ramarozatovo, Fahafahantsoa Rapelanoro Rabenja

Faculty of Medicine, University of Antananarivo, Antananarivo, Madagascar

Email address:

lulubslj@gmail.com (Mendrika Fifaliana Rakotoarisaona), nasendrefa@yahoo.fr (Fandresena Arilala Sendrasoa), aina_andrianarison@yahoo.fr (Malalaniaina Andrianarison), oni.raha@gmail.com (Onivola Raharolahy), harnjart9@gmail.com (Naina Harinjara Razanakoto), satamoril9@gmail.com (Moril Sata), tantell04@gmail.com (Volatantely Ratovonjanahary), irinamami@yahoo.fr (Irina Mamisoa Ranaivo), lsramarozatovo@gmail.com (Lala Soavina Ramarozatovo), frapelanoro@gmail.com (Fahafahantsoa Rapelanoro Rabenja)

To cite this article:

Mendrika Fifaliana Rakotoarisaona, Fandresena Arilala Sendrasoa, Malalaniaina Andrianarison, Onivola Raharolahy, Naina Harinjara Razanakoto, Moril Sata, Volatantely Ratovonjanahary, Irina Mamisoa Ranaivo, Lala Soavina Ramarozatovo, Fahafahantsoa Rapelanoro Rabenja. Cutaneous Manifestations in Chronic Hemodialysis Patients in Antananarivo Madagascar. *International Journal of Clinical Dermatology*. Vol. 5, No. 1, 2022, pp. 6-10. doi: 10.11648/j.ijcd.20220501.12

Received: August 9, 2022; **Accepted:** September 7, 2022; **Published:** September 16, 2022

Abstract: *Introduction:* Skin manifestations in chronic hemodialysis patients are frequent and polymorphous. The pathogenesis of these skin manifestations is poorly elucidated. The aim of this study was to determine the prevalence and clinical characteristics of these skin lesions and to review the literature on their pathogenesis. *Methods:* A descriptive multicenter cross-sectional study over 2-month period (November to December 2017) was conducted among chronic hemodialysis patients in 5 dialysis centers in Antananarivo Madagascar. *Results:* The study included 129 patients, 79 men and 50 women with a mean age of 53.4 years. The average duration of hemodialysis was 32.1 months. All patients presented at least one skin manifestation. Skin xerosis (72.97%), hyperpigmentation (70.54%) and pruritus (58.14%) were the most frequent specific signs of hemodialysis. Other non-specific signs found were acne (10.5%), prurigo (0.7%), ecchymosis (1.55%) and skin infections (10.8%). Only two patients had Kyrle's disease. Exoskeleton abnormalities were found in 44.19% of cases, represented essentially by onychomycosis (50%). According to our study, these cutaneous manifestations were not related to age or gender. *Conclusion:* Skin manifestations in chronic hemodialysis patients are frequent and deserve to be known by dermatologists. A good management of these conditions can reduce their prevalence and thus improve patient's quality of life.

Keywords: Cutaneous Manifestations, Hemodialysis, Madagascar, Uremic Pruritus, Xerosis

1. Introduction

Hemodialysis is an extrarenal replacement therapy that represents the most widely used treatment modality for end-stage renal disease. It prolongs the life expectancy of patients with chronic kidney disease (CKD). However, multivisceral complications that may be related either to the CKD or to the hemodialysis technique itself have altered the quality of life of these patients [1]. Among these complications, skin involvement is frequent and of variable severity [2, 3]. The prevalence of dermatological consultation in uremic patients is increasing due to these skin problems. A cross-sectional study of skin manifestations in chronic renal failure patients

treated by hemodialysis was conducted. The aim was primarily to determine the prevalence of these dermatological manifestations and secondarily to describe their clinical characteristics and finally to review the literature.

2. Methods

It was a descriptive cross-sectional multicenter study, conducted from november to december 2017 in chronic hemodialysis patients in Antananariavo Madagascar. Five hemodialysis centers have been selected, including two public and three private centers: the hemodialysis services of the Joseph Ravohangy Andrianavalona University Hospital

(CHUJRA), the Joseph Raseta Befelatanana University Hospital (CHUJRB), the Funds Health Center (FUNHECE), the Mpitsabo Mikambana hospital (MM24) and the Ilafy Polyclinic. These centers received respectively 12 patients, 12 patients, 28 patients, 90 patients and 6 patients for a four-hour hemodialysis session, one to three times a week. All patients who agreed to participate in the study and who had been under hemodialysis for at least 2 months were included. Patients with acute renal failure receiving hemodialysis as an emergency were not included.

An interrogation with a complete clinical and dermatological examination were systematically performed. The epidemiological data, the history, the dermatological functional signs were collected in the anamnesis. The installation mode, the triggering factors, in particular the drug-related causes and the evolution of the cutaneous manifestations were also specified in the anamnesis. The dermatological examination characterized the clinical aspect and the topography of the lesions. Biological tests as part of the follow-up of hemodialysis patients usually included a blood count, plasma creatinine concentration and electrolytes concentration, blood uremia, serum calcium and inorganic phosphorus. Other paraclinical tests were requested according to the clinical situation. All the data collected were recorded on a pre-established information sheet.

3. Results

3.1. General Characteristics of the Population

Among the 148 patients recruited, 129 patients were selected, including 79 men (61.24%) and 50 women (38.76%) with a sex ratio of 1.58. The mean age of the patients was 53,1 years (13 to 79 years). Patients in the age group 55 to 65 years were most involved. The total duration of hemodialysis ranged from 2 to 240 months. Eighty-eight percent of the patients performed hemodialysis three times a week, 8.53% twice a week and 3.10% weekly. The most frequent etiology of renal failure were hypertensive nephropathy (38.78%) and diabetic nephropathy (31.78%). In 10.5% of cases, CKD was of undetermined cause. CKD causes are shown in Table 1. Concerning the associated comorbidities, there were 75 cases of arterial hypertension, 49 cases of diabetes mellitus, 4 cases of heart disease, 1 case of asthma as given in table 2. Only 46% of the patients had biological tests before hemodialysis.

Table 1. Etiologies of CKD.

Affection	Number of cases n=129	Percentage 100%
Hypertensive Nephropathy	50	38,76
Diabetic nephropathy	41	31,78
Glomerular nephropathy	5	3,88
Tubulointerstitial nephropathy	8	6,20
Congenital small kidneys	1	0,78
Obstructive nephropathy	2	1,55
Other	8	6,20
Undetermined	14	10,5

Table 2. Comorbidities.

Comorbidity	Number of cases n=132	Percentage 100%
Cardiopathy	4	3,10
Diabete mellitus	49	37,98
Hypertension	75	58,14
Gout	2	1,6
Hepatitis C virus	1	0,8
Asthma	1	0,8

3.2. Skin Manifestations

All patients had at least one skin manifestation. The prevalence of cutaneous abnormalities in chronic hemodialysis patients is shown in Table 3.

Table 3. Main skin manifestations.

Skin abnormality	Number of cases n (%)
Xerosis	94 (72,97)
Hyperpigmentation	91 (70,54)
Pruritus	75 (58,14)
Kyrle's disease	2 (1,55)
Hair and nails affection	2 (1,55)
Ecchymosis	2 (1,55)
Vitiligo of venous access	2 (1,55)
Skin infections	14 (10,8)
Acne	9 (10,5)

Cutaneous xerosis was present in 72.86% of patients. It was frequently localized on the lower limbs in 82.9% of patients, and diffuse in 17.02% of cases. In 2 cases, the xerosis of the legs was severe giving an ichthyosiform appearance (Figure 1).

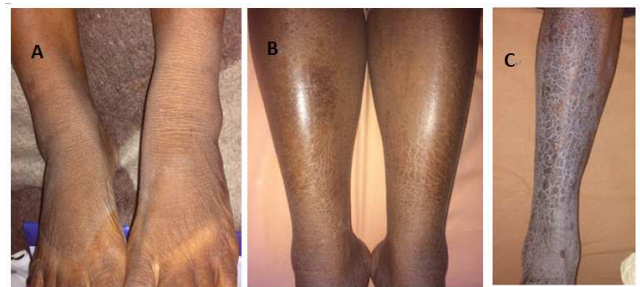

Figure 1. Mild (A), (B) moderate, (C) severe xerosis of the leg with ichthyosiform appearance.

Pruritus was present in 58.14% of cases. It appeared before hemodialysis in 10.2% of cases, during hemodialysis in 11% of cases and after hemodialysis in 21% of cases. Pruritus was localized in 31.58% and was mainly on the back (25 cases). It was diffuse in 68.42%. It was associated with other cutaneous signs such as skin xerosis in 56% of patients, scratching lesions in 18% of patients (excoriation, lichenification). Pruritus had no fixed schedule in 76 patients. It was disabling in 14% of patients and tolerable in 86% of patients. The prevalence of pruritus decreased with the age of hemodialysis, but was not related to the sex or age of the patients. Among the patients with pruritus, 27 patients had a phosphorus level measurement and a hyperphosphorus was present in 19 patients.

In 91 patients (70.54%), a localized skin hyperpigmentation was observed. It was frequently localized

in the photoexposed areas, with the face being the most affected in 45% of cases. Lesions were observed in the form of hyperpigmented macular plaques, poorly limited, asymptomatic and taking a melanoderma appearance (Figure 2). The patients phototype varied from IV to VI. The prevalence of hyperpigmentation increased with age of dialysis. It was common in patients with more than 2 years of dialysis.

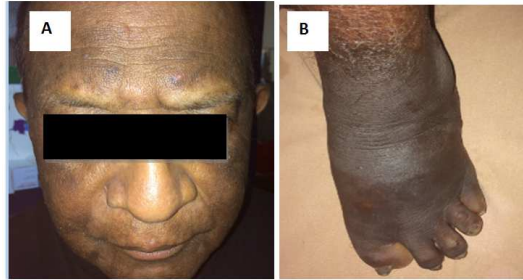


Figure 2. Skin hyperpigmentation: (A) on the face, (B) on the feet.

Kyrle's disease was noted in 2 cases. The patients had a history of diabetes mellitus treated with insulin. They complained of intense pruritus. Dermatological examination found brownish-red papulo-nodules with a central yellowish keratotic plug on the body trunk, extension face of limbs and buttocks (Figure 3). A skin biopsy could not be performed due to a financial problem.

Skin infections were observed in 14 patients. Mycotic infections were present in 9 cases, including 4 cases of seborrheic dermatitis, 3 cases of dermatophytosis and 3 cases of pityriasis versicolor. There were 3 cases of bacterial infections observed including folliculitis, pyoderma and furuncle lesions.

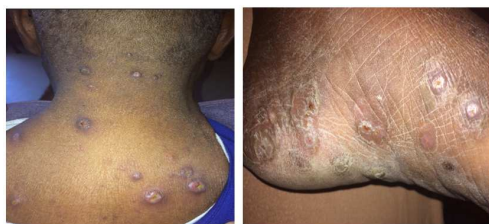

Figure 3. Kyrle's disease on the back and foot with a papulo-nodule centred by a yellowish horny plug.

Hair and nail damages were present in 44.19% of patients. Among these manifestations, hair loss was the most frequent observed in 27.91% of cases. Nail involvement was observed in 16.28% of cases. Onychomycosis was the most common nail changes, present in half of the cases (50%) followed by onychodystrophy (27.27%), Lindsay's nail (13.64%), brachyonychia (9.09%) (Figure 4).

Further skin lesions were found which are:

- 1) Prurigo (Figure 5A)
- 2) Vitiligo at the level of the venous approaches in 2 cases (Figure 5B)
- 3) Ecchymosis in 2 cases (Figure 5C)
- 4) Facial acne in 9 cases (Figure 5D)

No cases of late cutaneous pseudoporphyria, neither cutaneous calcification nor cutaneous amyloidosis were observed in this series.

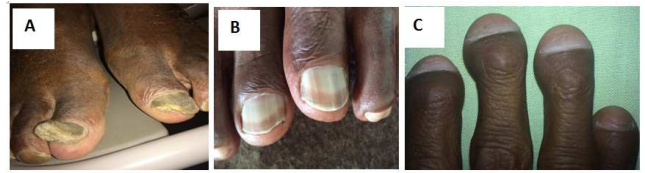

Figure 4. (A) onychomycosis. (B) Lindsay's nail ou half and half nails. (C) brachyonychie.

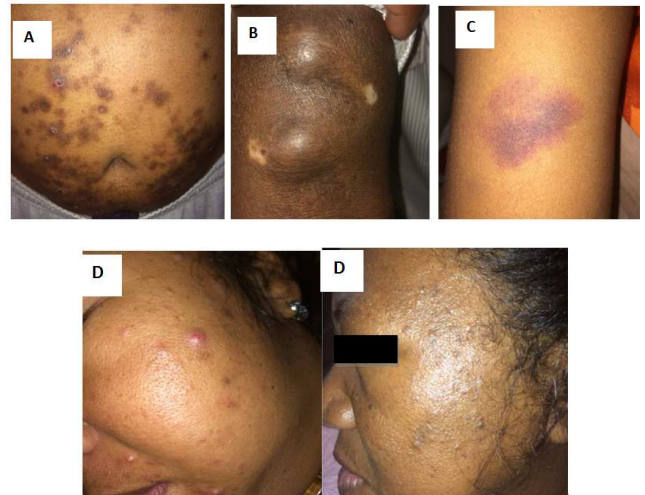


Figure 5. (A) Prurigo, (B) vitiligo of venous access, (C) ecchymosis, (D) facial acne.

4. Discussion

Dermatological lesions associated with CKD were known since the 19th century [4]. The frequency of cutaneous manifestations in chronic hemodialysis patients varies according to the series, ranging from 50 to 100% of cases [5, 6]. This study found a high prevalence of skin disorders. All patients had at least one skin sign. This finding is similar to what Basma Mourad et al in Egypt and Noama Dahbi et al in Morocco found as a result in their study [6, 7].

4.1. Xerosis

Cutaneous xerosis was the most common skin manifestation in this study (72.97%), which is consistent with the results of other studies conducted in India [5, 8-10]. It was also the most frequent skin manifestation among patients with chronic renal failure in pre-dialysis (72.2%). In some African studies, a predominance of skin xerosis was also observed with a prevalence of 96% in Morocco and 67.4% in Burkina Faso [11, 12]. In contrast, a study in Iran reported a lower rate of 23% of skin xerosis [13]. This difference might be related to the environmental and climatic factors as their study was conducted in a humid region.

The pathogenesis of xerosis is still poorly known. Several factors related to both hemodialysis techniques and renal failure are discussed. These factors include: hypervitaminosis

A, increase of retinol binding protein blood concentration, skin alkalinity, protein-energy malnutrition secondary to a severe diet, diuretic treatment, chemically induced irritation, glycerol deficiency associated with functional abnormalities, and decreased size of eccrine sweat glands responsible for skin dehydration [14, 15].

4.2. Hyperpigmentation

Pigmentation disorders represented by hyperpigmentation of the uncovered body areas were also common in uremic dialysis patients. Hyperpigmentation was present in 70.54% of our patients. The prevalence of hyperpigmentation was variable in the series. A lower rate was objectified by Morton et al (20%) [26]. In contrast, Dahbi N. et al found a high prevalence of 94%. This Moroccan study suggests the role of environmental factors that could explain this high rate of hyperpigmentation, particularly the hot and sunny climate that characterizes this country with the absence of photoprotection [11].

This hyperpigmentation would be secondary to the increase in the tissue level of β -MSH (β -Melanin Stimulating Hormone) resulting from the lack of renal excretion of this hormone, which is also a non-dialyzable hormone responsible for an increased melanogenesis [8]. Ultraviolet light increases melanin synthesis under the action of this hormone; Hence, the hyperpigmentation predominating in photoexposed areas. Hemosiderosis is another factor that could increase skin hyperpigmentation, observed especially in polytransfused patients. In some studies, hyperpigmentation was correlated with long dialysis duration and diuresis quantity < 500 mL/day [27, 28].

4.3. Pruritus

Pruritus was also a frequent symptom in this study (58.14%). Basma *et al.* and Sutan MM *et al.* reported similar results and found respectively a prevalence of 51.6% and 55% [6, 16]. A difference in the prevalence of pruritus was observed in the literature according to the period of the study. The prevalence of pruritus was between 70-90% in the older series compared to 20-65% in the recent studies, which are joining the results of our study [5, 6, 8, 17-20]. This decrease in the prevalence of pruritus would be related to the improvement of the dialysis technique. In our study, pruritus was not correlated with age or gender, which is consistent with other studies. The clinical characteristics of the pruritus: diffuse, intense, without a fixed schedule and accompanied by scratching lesions mainly on the back confirmed its uremic origin. The severity of pruritus was variable in the literature. It was usually source of sleep disorder and disruption of patients' daily activities [21-23].

The pathogenesis of pruritus is poorly elucidated and is multifactorial. Uremic pruritus is mainly due to skin xerosis and elevated phosphorus with secondary hyperparathyroidism. several hypothesis were also suggested such as stress, vitamin A metabolism abnormalities, peripheral neuropathy, elevated serum histamine and skin mast cells. However, the majority of studies have not found a

significant link between these factors and the occurrence of pruritus. Thus, pruritus treatment remains non-specific and involves emollients, antihistamines, ultraviolet B phototherapy and, depending on the context, parathyroidectomy [13, 24]. The nephrogenic pruritus is refractory to treatment and renal replacement is the only definitive treatment [25].

4.4. Kyrle's Disease

Kyrle's disease is a perforating dermatosis acquired during chronic renal failure. It is often associated with diabetes. Clinically, it is characterized by papules, keratotic follicular and perifollicular nodules with a central horny plug giving an umbilical appearance (Figure 3). It is responsible of severe pruritus and chronic scratching [29]. Kyrle's disease is rare and its prevalence varies from 4.5 to 11% depending on the series [3, 30, 31]. Only 2 patients aged 56 and 70 year-old, diabetics, had a probable Kyrle's disease in our study.

The exact etiopathogenesis of this condition remains unclear. Several hypothesis have been suggested such as diabetic microangiopathy, microtrauma due to scratching, acquired collagen and/or elastic fiber abnormalities, dysregulation of vitamin A and/or vitamin D metabolism and immune dysfunction. There is no specific treatment, topical corticosteroids, local vitamin A and UVB are commonly used.

4.5. Hair and Nail Changes

Hair abnormalities such as diffuse hair loss, brittleness and dryness were found in the literature. The frequency of this hair anomaly varied between 25 and 30%, which is comparable with our study. Hair changes may be caused by malnutrition, hyposideremia and stress [5, 8].

Onychomycosis was the most frequent nail affection in our series. It was observed in 50% of cases, which is consistent with the literature. The risk factors for onychomycosis were diabetes, long duration of hemodialysis and onychodystrophy [32]. The Lindsay's nails or half and half nails (figure 4B) which is specific to hemodialysis was found in 13.64% of cases, a lower rate compared to the literature [5, 8].

5. Conclusion

This study confirms the high prevalence of skin manifestations in chronic hemodialysis patients in a context of lack of resources. They are mainly represented by skin xerosis, hyperpigmentation and pruritus. The pathogenesis of these skin disorders is not well known. Skin diseases in these patients can both alter their quality of life and lead to depression requiring adequate management.

References

- [1] Pastan S, Bailey J. Medical progress: dialysis therapy. N England J Med. 1998; 338: 1428-37.

- [2] Shrestha P, Mathur M. Dermatologic Manifestations In: Chronic kidney disease patients on hemodialysis. *Nepal J Dermatol Venereol Leprol.* 2016; 12 (1): 34-40.
- [3] Pico MR, Lugo-Somolinos A, Sanchez JL, Burgos-Calderon R. Cutaneous alterations in patients with chronic renal failure. *Int J Dermatol.* 1992; 31: 860-3.
- [4] Bright R. Cases and observations illustrative of renal disease. *Guys Hospital Rep.* 1836; 1: 338-79.
- [5] Thomas EA, Pawar B, Thomas A. A prospective study of cutaneous abnormalities with chronic kidney disease. *Indian Journal of Nephrology*, 2012; 22 (2): 116-120.
- [6] Basma M, Doaa H, Kamal O, Sarah R. Dermatological changes in patients under hemodialysis. *Clinical, Cosmetic and Investigational Dermatology.* 2014: 7.
- [7] Szepletowski JC, Sikora M, Kusztal M, Salomon J, Magott M, Szepletowski T et al. Uremic pruritus: a clinical study of maintenance hemodialysis patients. *J Dermatol.* 2002; 29: 621-7.
- [8] Deshmukh SP, Sharma YK, Dash K, Chaudhari NC, Deo KS. Clinicoepidemiological study of skin manifestations in patients of chronic renal failure on hemodialysis. *Indian Dermatol Online J.* 2013; 4: 18-21.
- [9] Mirza R, Wahid R, Talat H. Dermatological manifestations in chronic renal failure patients on haemodialysis. *JLUMHS.* 2012; 11 (1): 24-8.
- [10] Swarna KG, Sowmya S, Nageswaramma S, Rama M Cheedirala, Vani T. A clinical study of cutaneous manifestations in patients with chronic kidney disease. *IOSR Journal of Dental and Medical Sciences (IOSR-JDMS).* 2015 oct; 14: 07-17.
- [11] Dahbi N, Hocar O, Akhdari N, Amal S, Bassit N, Fadili W et al. Cutaneous manifestations in hemodialysis patients. *Nephrol Ther.* 2014 Avr; 10 (2): 101-10.
- [12] Gérard C, Nina KS, Dorisse FYF, Yacouba N, Adama RK, Alban B. Cutaneous manifestations in patients on chronic hemodialysis in a developing country. *Pan Afr Med J.* 2016; 24: 110.
- [13] Hajheydari Z and Makhloogh, "Cutaneous and mucosal manifestations in patients on maintenance hemodialysis: a study of 101 patients in Sari, Iran," *Iranian Journal of Kidney diseases*, 2008; 2: 86-90.
- [14] Guillet G, Sanciaume C, Hehunstre JP, Bondonny JM, Maleville J. Generalized pilar keratosis and hypervitaminosis A in a child with renal insufficiency. *Ann Dermatol Venereol.* 1982; 109: 1061-6.
- [15] Yosipovitch G, Reis J, Tur E, Sprecher E, Yarnitsky D, Boner G. Sweat secretion, stratum corneum hydration, small nerve function and pruritus in patients with advanced chronic renal failure. *Br J Dermatol* 1995; 133: 561-4.
- [16] Sultan MM, Mansour HH, Wahby IM, Houdery AS. Cutaneous manifestations in Egyptian patients with chronic renal failure on regular haemodialysis. *J Egypt Women Dermatol Soc.* 2010; 7 (1): 49-55.
- [17] Mathur VS, Lindberg J, Germain M, Block G, Tumlin J, Smith M et al. A longitudinal study of uremic pruritus in hemodialysis patients. *Clin J Am Soc Nephrol.* 2010; 5: 1410-9.
- [18] Bah AO, Balde MC, Kaba ML, Camara A, Cisse A, Bah MO, Diakite M. Cutaneous manifestations of chronic renal. *Ann Dermatol Venereol.* 2008; 135: 318-20.
- [19] Akhyani M, Ganji MR, Samadi N, Khamesan B, Daneshpazhooh M. Pruritus in hemodialysis patients. *Biomed Central Dermatol.* 2005; 5: 7.
- [20] Masmoudi A, Ben Hmida M, Mseddi M, Meziou TJ, Walha N, Hachicha J et al. Cutaneous manifestations of chronic hemodialysis: prospective study of 363 cases. *Presse Med.* 2006; 35: 399-406.
- [21] Zucker L, Kosiporitch G, David M, Gaftor U, Boner G. Prevalence and characterization of uremic pruritus in patients undergoing hemodialysis: uremic pruritus is still a major problem for patients with end-stage renal disease. *J Am Acad Dermatol.* 2003; 49 (5): 842-846.
- [22] Naderi N, Mahdavi-Mazdeh M, Firouz A, Heydari Seraj M. Cutaneous manifestations of end stage renal disease under hemodialysis in hemodialysis ward at Imam Khomeini hospital in Tehran in 2003. *Iran J Dermatol.* 2005; 6: 489-495.
- [23] Udayakumar P, Balasubramanian S, Ramalingam KS, Lakshmi MC, Srinivas CR, Mathew AC. Cutaneous manifestations in patients with chronic renal failure on hemodialysis. *Indian J Dermatol Venereol Leprol.* 2006; 72: 119-125.
- [24] Tsukahara K, Takema Y, Moriwaki S, Fujimura T, Imokawa G. Dermal fluid translocation is an important determinant of the diurnal variation in human skin thickness. *Br J Dermatol.* 2001; 145 (4): 590-596.
- [25] Maheshwari C, Kumar A, Gupta S. A clinico-epidemiological study of cutaneous changes in chronic kidney disease. *Int J Res Dermatol.* 2016 Dec; 2 (4): 103-108.
- [26] Morton CA, Lafferty M, Hau C, Henderson I, Jones M, Lowe JG. Pruritus and skin hydration during dialysis. *Nephrology Dialysis Transplantation.* 1996; 11 (10): 2031-2036. [PubMed] [Google Scholar].
- [27] Headley CM, Wall B. ESRD-associated cutaneous manifestations in a hemodialysis population. *Nephrol Nurs J.* 2002; 29 (6): 525-527, 531-539. 20.
- [28] Moon SJ, Kim DK, Chang JH, et al. The impact of dialysis modality on skin hyperpigmentation in haemodialysis patients. *Nephrol Dial Transplant.* 2009; 24 (9): 2803-2809.
- [29] Chang P, Fernandez V. Acquired perforating disease: report of nine cases. *Int J Dermatol.* 1993; 32: 874-6.
- [30] Patterson JW. The perforating disorders. *J Am Acad Dermatol.* 1984; 10: 561-81.
- [31] Morton CA, Henderson IS, Jones MC, Lowe JG. Acquired perforating dermatosis in a British dialysis population. *Br J Dermatol.* 1996; 135: 671-7.
- [32] Kuvandik G, Cetin M, Genctoy G, Horoz M, Duru M, Akcali C et al. The prevalence, epidemiology and risk factors for onychomycosis in hemodialysis patients. *Biomed Central Infect Dis.* 2007; 7: 102.